

# EFFICACY OF PHOTODYNAMIC THERAPY IN THE SHORT AND MEDIUM TERM IN THE TREATMENT OF ACTINIC KERATOSIS, BASAL CELL CARCINOMA, ACNE VULGARIS AND PHOTOAGING: RESULTS FROM FOUR CLINICAL TRIALS

Martínez-Carpio PA<sup>1,2,\*</sup>, Alcolea-López JM<sup>2</sup>, Vélez M<sup>3</sup>.

1: IMC-Investiláser. Sabadell. Barcelona. Spain.

2: Clínica Alcolea. Barcelona. Spain.

3: Dermatology Department. Hospital Universitario del Mar. Barcelona. Spain.

**Objective:** To determine the clinical efficacy of methyl-aminolevulinate (MAL)-Photodynamic Therapy (PDT) in the treatment of actinic keratosis (AK), basal cell carcinoma (BCC), acne vulgaris (AV) and photoaging (PA), in the short and medium term.

**Subjects and methods:** Four separate prospective studies were designed on patients with AK (n=25), BCC (n=20), AV (n=20) and PA (n=25). Two PDT protocols were applied, and different clinical efficacy criteria were established, including lesion count and size. Two semi-quantitative and four analogue visual scales were completed for the evaluation of results according to the therapist, the patient and two independent experts.

**Results:** In the AK and BCC studies, full clinical remission was observed in 84.7% and 75.7% of lesions, respectively. In the AV study, the number of inflammatory and non-inflammatory lesions fell significantly ( $p < 0.001$ ,  $p < 0.05$ ). In the PA study a reduction in Dover scale scores (3.19 vs. 2.14,  $p < 0.001$ ) was proven. The percentages of satisfied or very satisfied patients were: AK=88%, BCC=90%, AV=89% and PA=80%. A year later, none of the AK or BCC lesions had reappeared, and the cases of AV and PA remained stable, with a tendency towards improvement.

**Conclusion:** the MAL-PDT procedures used produced efficacious, safe and satisfactory results in KA, BCC, AV and PA in the short and medium term.

**Key words:** methyl-aminolevulinate, photodynamic therapy, actinic keratosis, basal cell carcinoma, acne vulgaris, photoaging, photorejuvenation.

## Introduction

Photodynamic therapy (PDT) is a method used with increasing frequency to treat a variety of cutaneous conditions. The procedure consists of applying a photosensitive compound (photosensitizer) which is subsequently lit at a wavelength within its absorption spectrum. This enables selective action to focus on altered, cancerous or pathological cells. Within the scope of

dermatology, the Food and Drug Administration (FDA, USA) initially only authorised this technique for the treatment of actinic keratosis (AK) and basal cell carcinoma (BCC), but its off-label use has been researched for many other conditions. Among the most prevalent are acne vulgaris (AV) and photoaging (PA). The information available seems to be sufficient to justify the use of PDT for these four disorders, but there is a certain amount of controversy regarding the degree of efficacy compared with other therapies. Moreover, considerable variability has been observed between the materials and methods used by the different authors,

### Addresssee for Correspondence:

Pedro A. Martínez-Carpio MD, PhD.  
IMC-Investiláser.  
C/ Sarret, 13  
08205 Sabadell (Barcelona) Spain  
E-mail: [pmc@investilaser.com](mailto:pmc@investilaser.com)

Manuscript received: July 26th, 2012

Accepted for publication: August 31st, 2012

which could influence the results achieved<sup>1)</sup>.

The benefits attributed to PDT focus on the fact that it is a safe, effective, non-invasive method with few side effects and which yields very satisfactory cosmetic results. Among the disadvantages claimed by some experts is that the same or even better and more cost-effective results can be obtained with other therapies, and that there is little information on the effect achieved in the medium and long term.

AK, BCC, AV and PA are frequent ailments for which there are several effective treatments. The importance and objective of treatment for AK and BCC are focused on their malignant transformation potential; intervention therefore must be geared towards eradication of the lesion and prevention of recurrence<sup>2-6)</sup>. In AV and PA cases, the aim is the maximum reduction in number of lesions and to achieve an aesthetic improvement<sup>7-9)</sup>. However, and particularly in exposed and visible areas, cosmetic results are always important for the patient.

In real-life practice each therapy is selected according to the type of disorder, the therapist's knowledge and the patient's intention and expectations. The physician informs the patient of the possibilities, benefits and disadvantages of each therapy and the patient has the last word. One of the most important factors for both the physician and the patient when deciding on the treatment is its expected efficacy and success; hence the importance of well documented data on therapeutic efficacy and patient satisfaction. The trials, in which the clinical efficacy of PDT in the abovementioned conditions is examined, from a practical perspective, are few and highly heterogeneous. Biopsies and laboratory methods are often included in order to observe changes in treated lesions, but little attention is paid to the clinical and aesthetic appearance of the lesions. Results depend on methods used and assessment is difficult in that it depends on the subjectivity of the assessors. There is even less information available on results in the medium and long term.

The aim of this work is to offer an in-depth examination of the clinical efficacy of PDT procedures in terms of measurable and patient-satisfaction results, in the short and medium term. To this end we have included a wide range of measurements, all previously validated by the scientific literature, applied in four independent clinical trials.

## Patients, Materials and Methods

Four prospective studies were designed with the prin-

cipal objective of studying the clinical efficacy of our PDT procedures, in the short and medium term, in the treatment of AK (n=25), BCC (n=20), AV (n=20) and PA (n=25) in exposed areas. Each study comprises an open clinical trial, with both open and blind assessments of results, and data on safety, adverse effects and degree of patient satisfaction.

Each participant was recruited by systematic random selection from scheduled visits at Clínica Alcolea (Barcelona, Spain), between February and November 2010. All subjects agreed to the terms and conditions for inclusion in the study and undertook to present to the subsequent control and follow-up visits at set dates. The assays were conducted according to the Declaration of Helsinki and all patients signed a written informed consent before inclusion into each study.

The general inclusion criteria were: to present a lesion eligible for treatment, to have no medical contraindications to the treatment and to accept trial participation conditions. General exclusion criteria were to present a serious organic disorder, incipient or established cognitive impairment, pregnancy, lactation, to be receiving oral or parenteral pharmacological therapy which might interfere with the results, laser or phototherapeutic treatment and/or prior surgery on the area of interest. Patients using topical treatments were not excluded, but such treatments were withdrawn one week before beginning PDT therapy and remained so until completion of the study. Additional and specific inclusion and exclusion criteria were established for each group, as mentioned below.

Subjects were individually informed on the lesions to be treated in each specific case (based on the pertaining photographs) and on the foreseeable and realistic improvements expected on such lesions. Explanations were provided to each individual on how to complete the analogue efficacy scale.

**Actinic keratosis (AK):** The study included 25 patients, 9 men and 16 women (age range=48-87 years, mean=66.2 years), presenting a total of 59 actinic keratosis lesions measuring over 10mm, at different stages of evolution, located on the face or scalp. All cases were primary, multiple or large sized lesions which had not been subjected to any previous treatment. The diagnosis of AK was clear-cut, based on clinical and dermoscopic characteristics. All patients received two sessions of the PDT-1 protocol, separated by a three week interval. The larger diameter of each lesion was measured in millimetres. Clinical efficacy was assessed as complete upon full disappearance of the lesion, no longer palpable or visible, and otherwise was classified

as partial. The pertaining clinical efficacy scales were also completed.

**Basal Cell Carcinoma (BCC):** The study included 20 patients, 13 men and 7 women (age range=54-93 years, mean=71.3 years), presenting a total of 33 BCC, 24 superficial and 9 nodular BCCs, located on face or scalp. The larger diameter of each lesion was measured in millimetres. All cases were primary lesions which had not been subjected to any previous treatment. The diagnosis of BCC was clinical and/or dermoscopic. All subjects received two sessions of the PDT-1 protocol with a three week interval between each session. Efficacy was evaluated in accordance with the criteria of Surrenti et al <sup>4)</sup>: complete response (clinical disappearance of BCC), partial response (>40% and <100% reduction in tumour size) and insufficient response (<40% reduction in tumour size). The pertaining clinical efficacy scales were completed.

**Acne vulgaris (AV):** 20 patients were included in this study, 9 men and 11 women (age range=15-34 years, mean=25.3 years), presenting a total of 484 acne lesions, exclusively on the face. The number of non-inflammatory lesions (open and closed comedones) and inflammatory lesions (papules, pustules and nodulocystic lesions) were recorded for each patient. All patients received three sessions of the PDT-2 protocol, with a two-week interval between each session. Clinical efficacy was assessed as full when the acne lesion disappeared completely, neither visible nor palpable, and otherwise as partial. The pertaining clinical efficacy scales were completed.

**Photoaging (PA):** 25 patients were included, 8 men and 17 women (age range=37-83 years, mean=59.5 years), presenting objective signs of photoaging on face, hands and/or neck/chest. All cases were primary lesions which had not received any prior treatment, except for topical therapy in some cases. All subjects received three sessions of the PDT-2 protocol, each session separated by a two week interval. PA lesions were assessed using the 5-point (0-4) Dover scale, modified to enable photographic assessment of the areas treated <sup>10)</sup>. Possible changes in fine surface lines, mottled pigmentation, sallowness, wrinkling and global photodamage were assessed. The degree of PA was classified as 0=none, 1=slight, 2=moderate, 3=severe, 4=very severe. The corresponding clinical efficacy scales were completed.

## PDT procedures

The PDT-1 procedure was applied in cases of AK and BCC, whereas the PDT-2 procedure was used for cases of AV and PA.

PDT-1 procedure: 1) cleaning and removing oil from skin, curettage of thick lesions. 2) Application of MAL at 16% (Metvix®, PhotoCure, Oslo, Norway), rubbed into lesions. 3) Three hour incubation. 4) Radiation with red light LEDs of 633nm (Omnilux®, Phototherapeutics Ltd., Cheshire, UK), for 16 minutes, up to an overall dose of 105J/cm<sup>2</sup>.

PDT-2 procedure: 1) cleaning of skin with acetone to remove cutaneous lipid layer. 2) Application of MAL at 8% every 15 minutes for 1 hour, rubbing more intensely on the lesions 3) Incubation for one hour. 4) Radiation with red light LEDs of 633nm for 16 minutes, up to an overall dose of 105 J/cm<sup>2</sup>.

## Assessment of results using the clinical efficacy scales

All patients were assessed just prior to PDT treatment (baseline), one month into treatment (first assessment), and one year (second assessment) after the last PDT session. The clinical assessment, the counting of lesions, the application of the treatment, the follow-up and gathering of photographic images were carried out by a single researcher specialising in PDT dermatological therapies. During each evaluation, standardised frontal and bilateral 45° side photographs were taken using the same camera (Canon EOS300D-Digital, Tokyo, Japan) settings, lighting and patient positioning.

The following 5 point grading scale (compared with baseline observations) was established to assess changes in qualitative variables: 1 (worse: exacerbation), 2 (no change), 3 (fair), 4 (good) and 5 (excellent).

Finally, a series of efficacy Visual Analogue Scales (VAS) were used to indicate along a 100 millimetre horizontal line the subjective perception of the degree of severity of the lesions before and after the treatment. The distance in millimetres from the starting point of the line to each point indicated along it was used for statistical calculation.

VAS-I (therapist's assessment). (◆): degree of severity of lesions observed before treatment, where 0=no lesions and 100=very severe lesions. (▲): degree of severity observed one month after treatment. (■): degree of severity observed one year after treatment.

VAS-II (patient's assessment). (◆): degree of severity of lesions according to the impression of

patient before treatment, where 0=no lesions and 100=very severe lesions. (▲): degree of severity one month after treatment.

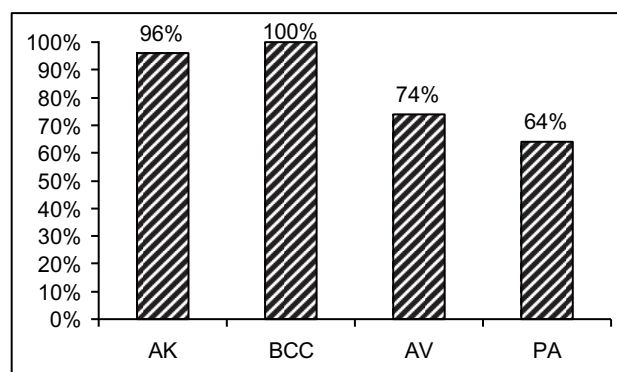
VAS-III (independent dermatologist's assessment, external to the study, based on the photographic images classified by patient: before, one month after and one year after). (◆): degree of severity of lesions photographed before treatment, where 0= no lesions and 100=very severe lesions. (▲): degree of severity one month after treatment. (■): degree of severity one year after treatment.

VAS-IV (assessment by independent plastic surgeon, external to the study, based on photographic images out of order, in reader-blinded mode), where 0=no lesions and 100=very severe lesions. The main researcher determined the allocation of the (◆) or (▲) marks according to the order of the photographs.

At the one-year follow-up, the same therapist observed the lesions, new photographs were taken and only the 5-point grading scale, VAS-I and VAS-III were completed. Study assessment was carried out on the basis of comparison with the first follow-up session, and not with those obtained at baseline.

### Side effects, complications and degree of patient satisfaction

Any possible complications and side effects (pain, erythema, oedema, post-inflammatory hypopigmentation or hyperpigmentation, scarring, milia, etc.) were recorded during post-intervention follow-ups. The subjective satisfaction at each assay was classified as follows: 1 (very dissatisfied), 2 (dissatisfied), 3 (somewhat satisfied), 4 (satisfied) and 5 (very satisfied).



**Figure 1:** Percentage of patients who obtained a good or excellent result one month after treatment, according to therapist' assessment.

### Long term maintenance topical treatment

After the first assessment, patients were informed of the importance of caring for the skin via maintenance topical treatments, such as mild soap, corticoid-free moisturising creams and exfoliators, and sun protectors.

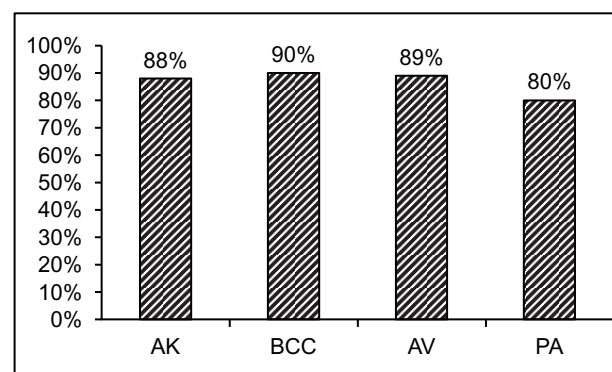
### Statistical analysis

Data was entered and processed using the SPSSv.13.0 for Windows program. Descriptive statistical data included the average value or arithmetic mean (m), the range (r) and the percentage (%).Categorical variables were represented by percentages and analyzed by the Chi-square or the Fisher exact tests. Treatment effects were compared from each follow-up measurement to the baseline scores using the paired Student-t test. A *p* value of <0.05 was considered statistically significant.

### Results

#### Actinic keratosis (AK)

The average lesion length before treatment was of 24.5mm (range=11-39). The average lesion length at first evaluation was of 3.7mm (range=0-12), showing a very significant reduction in the size of the lesions ( $p<0.0001$ ). Clinical efficacy was complete in 50 of the 59 lesions (84.7%), and incomplete in the rest (15.3%). The improvement in the 5-point grading scale was 1/25 fair (4%), 4/25 good (16%) and 20/25 (80%) excellent (**Fig.1**). Among the patients, 3/25 were somewhat satisfied (12%), 9/25 were satisfied (36%) and 13/25 were very satisfied (52%) (**Fig.2**).



**Figure 2:** Percentage of patients who stated they were satisfied or very satisfied one month after finishing the treatment.

At the one-year follow-up, in regard to the photographs taken at the first follow-up session, the results were: 4/25 (16%) worse, 16/25 (64%) no change and 5/25 (20%) fair. No recurrence was shown in patient examination.

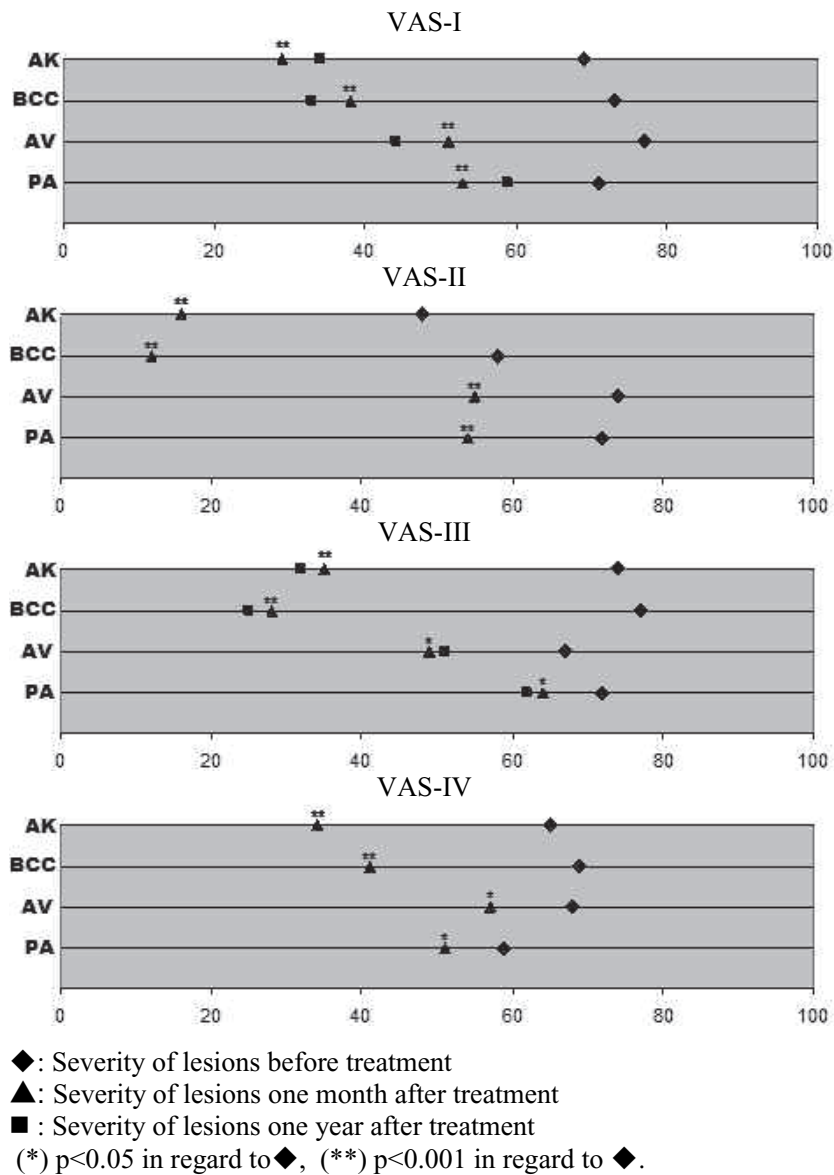
**Basal cell carcinoma (BCC)**

BCCs varied in size between 6 mm and 53 mm (mean:12mm). Complete response in the first evaluation was found in 22/24 superficial BCC (91.6%) and in 3/9 nodular BCC (33.3%), while partial response was

observed in 2/24 superficial BCC (8.3%) and in 6/9 nodular BCC (66.6%). Full clinical remission was observed in 75.7% of tumours.

The improvement in the 5-point grading scale was 7/20 good (35%) and 13/20 (65%) excellent (**Fig.1**). 2/20 patients stated they were somewhat satisfied (10%), 5/20 satisfied (25%) and 13/20 were very satisfied (65%) (**Fig.2**).

At the second assessment (after one year), no tumour recurrence whatsoever or significant changes therein were observed.



**Figure 3:** Visual Analogue Scales VAS-I, VAS-II, VAS-III and VAS-IV.



### Acne vulgaris (AV)

The average numbers of inflammatory and non-inflammatory lesions at baseline were 7.8 (r=2-19) and 16.4 (r=7-26) respectively. The same number after one month of treatment dropped to 4.1 (r=1-18) and 13.9 (r=3-22) ( $p < 0.001$  and  $p < 0.05$ , respectively). The improvement in the 5-point grading scale was 5/19 (26%) fair, 7/19 (37%) good and 7/19 (37%) excellent (**Fig.1**). 2/19 patients declared they were somewhat satisfied 2/19 (11%), 5/19 satisfied (26%) and 12/19 were very satisfied (63%) (**Fig.2**).

At the one-year follow-up, in comparison to the one-month photographs, the results were as follows: 2/18 (11%) worse, 9/18 (50%) no change and 10/18 (39%) fair.

### Skin Photoaging (PA)

The average score in the Dover scale at baseline was 3.19 (r=1-4). One month after the last session, the average score was 2.14 (r=0-3), showing a statistically significant reduction ( $p < 0.001$ ). The improvement in the 5-point grading scale was 3/25 (12%) no change, 6/25 (24%) fair, 10/25 (40%) good and 6/25 (24%) excellent (**Fig.1**).

5/25 patients were somewhat satisfied (20%), 13/25 were satisfied (52%) and 7/25 were very satisfied

(28%) (**Fig.2**).

At the one-year follow-up, in comparison to the photographs taken at the one-month follow-up session, the results were: 5/22 (23%) worse, 10/22 (45%) no change and 7/22 (32%) fair.

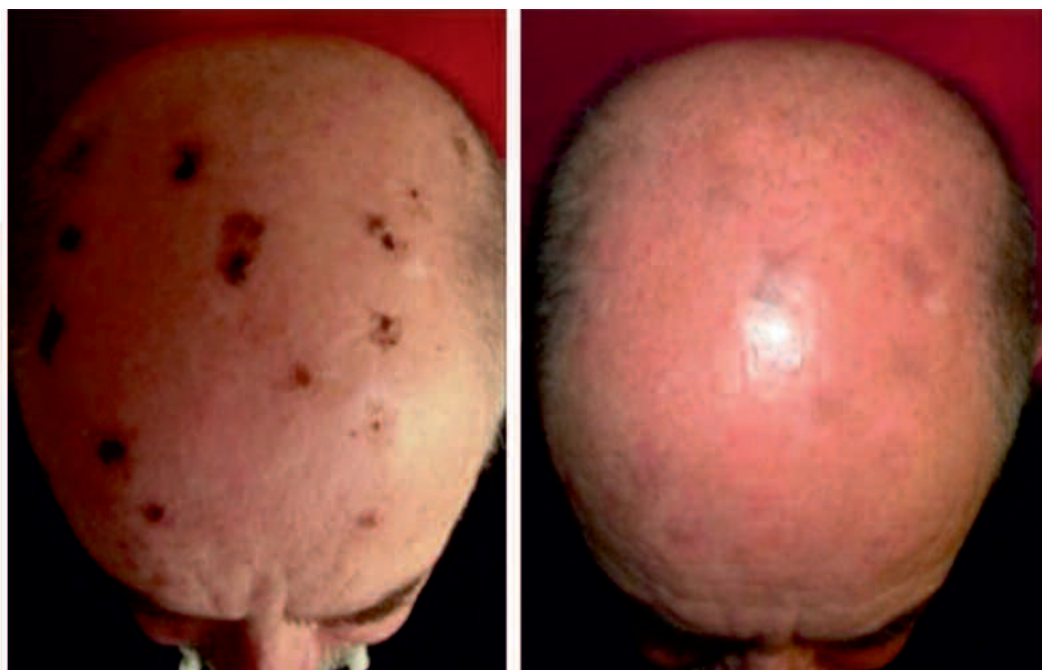
The average scores of the pertaining visual analogue scales (VAS-I, VAS-II, VAS-III and VAS-IV) are shown in **figure 3**. Statistically significant differences were found between the photographs taken prior to treatment and those obtained at one-month follow-up. Generally, a trend was observed at the one-year follow-up, albeit without statistical significance.

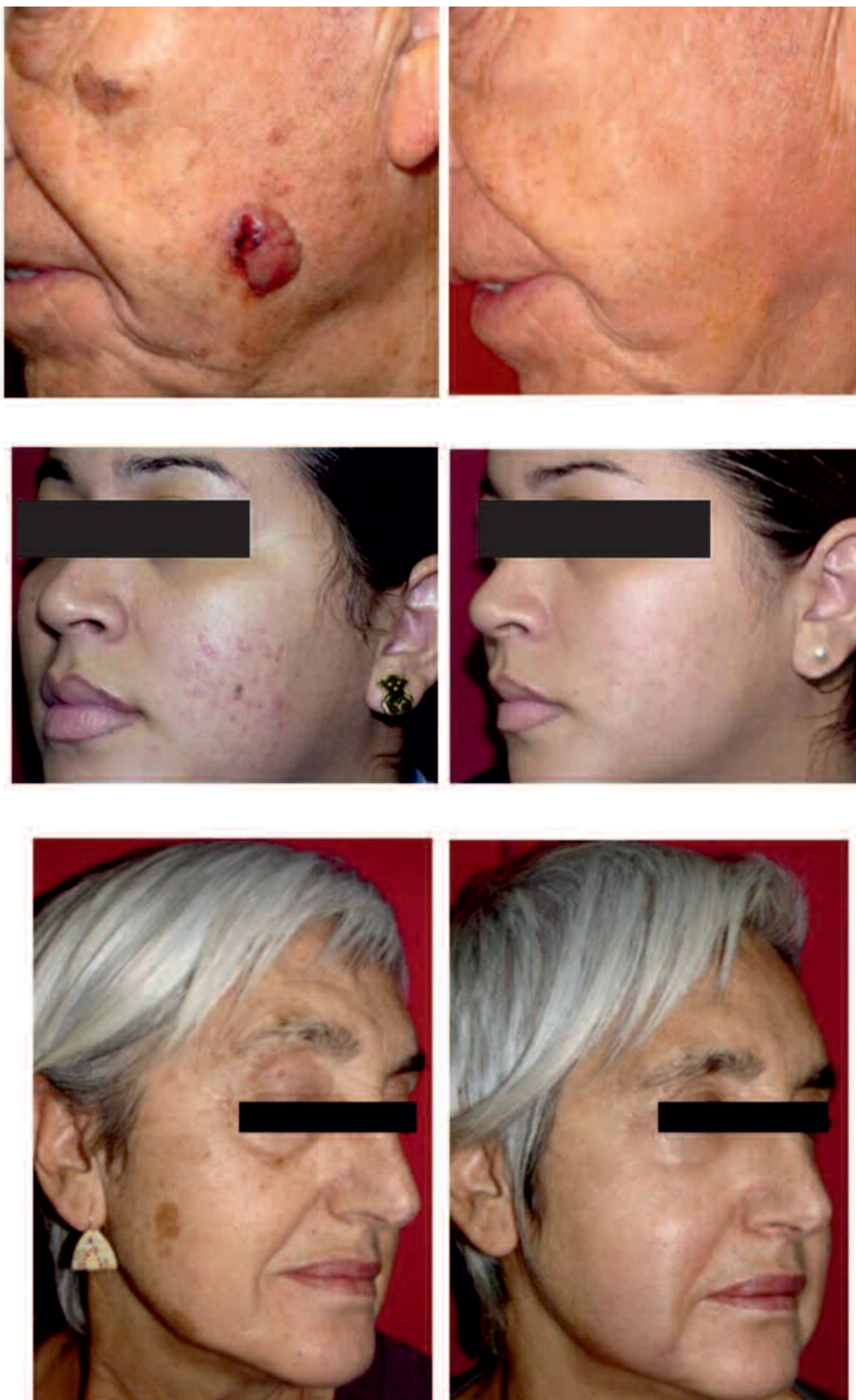**Figure 4** shows some photographs of the results assessed as excellent by the therapist.

### Safety, adverse effects and withdrawals

None of the patients experienced systemic adverse events or phototoxic reactions. All patients suffered noticeable pain and stinging during and after the light application, which subsided within 24 hours, as well as erythema, slight oedema and thin scars which disappeared within 3-5 days. Pain as a side effect was controlled by giving 1g paracetamol prior to treatment and cooling the irradiated area with a cold air device (Crio 6, Zimmer ElektroMedizin, Neu-Ulm, Germany), with a flow of 600 liters /minute.

In no case was treatment interruption required.





**Figure 4**

One patient from the AV group withdrew from the study before the first assessment, three patients from the PA group and one from the AV group withdrew before the second assessment. In all cases this was due to reasons unrelated to the actual studies.

## Discussion

Supported by statistical proof, the results confirm that the PDT procedures used are effective, safe and satisfactory in treating AK, BCC, AV and PA in exposed areas. As is mentioned in the introduction, we consider that clinical efficacy includes objective and measurable therapeutic efficacy, as well as the degree of satisfaction expressed by the patient for, even if the treatment works but fails to satisfy the patient, it will not succeed. The almost non-existent percentage of withdrawals is due to therapeutic adherence and the commitment of the trial participants, but also indicates that the treatment is well tolerated. Pain symptoms may be associated with higher fluencies used in our trials in comparison to fluencies reported in previous studies. However, fluencies used would be responsible for more evident effects of treated areas maintained through time in which extra irradiation will play a role increasing collagen neoformation with a higher efficacy of results.

In our opinion, the most significant characteristic is the level of coherence between most of the results, despite the variability among observers and the heterogeneity of the assessment scales. Moreover, the scores of each scale were allocated separately, and each assessor visualised the same photographs on various occasions, for allocation of the different scores. This gives rise to an intra-observer variability which justifies any non-significant discrepancies. However, coherence is observed among measurements of an objective nature (number and measurement of lesions, therapeutic efficacy scales) and of a subjective nature (VAS I, II, III and IV, degree of satisfaction). The fact that clinical efficacy is measured with different variables and scales and at different times, but with similar results is worth bearing in mind. For instance, in the case of BCC, the 5-point grading scale indicates that the results were good or excellent in 100% of tumours treated as all experienced a significant reduction in size. However, only 75.7% of tumours disappeared. Here the discrepancy is due to a set of different efficacy criteria: "good", "excellent", or "clinical disappearance of the tumour". On the other hand, improvement levels found in the VAS-IV scale are lower than those observed in the remaining visual analogue scales as the random

examination of the photographs (not knowing which pertain to before or to after the treatment) implies an unconditioned assessment. A statistical improvement in all trials is also shown here.

Previous studies have proven PDT to be very effective in the treatment of non-hypertrophic AK<sup>2,3,11</sup>. Tshen et al., recommend one or two treatment sessions, according to the case, reporting full healing in 86% of lesions four months after treatment<sup>11</sup>. Tarstedt et al. obtained even better results, with 93% of lesions having disappeared after a single session and confirmed 3 months after treatment<sup>2</sup>. Annemans et al. observed a full remission in 83% of AK, with an excellent cosmetic result in 95% of cases, at a maximum follow-up of 6 months<sup>3</sup>. Our data are in line with these and other publications, and reiterate the already proven efficacy for such conditions. Results were considered to be good or excellent in 96% of cases and patients stated that they were satisfied or very satisfied in 88% of cases. Lesions often disappear after a single session, but the double session with a three-week interval can help to improve the result and prevent subsequent recurrence. In the one-year follow-up no recurrence was observed, and the fact that most of the patients continued with the topical maintenance treatment must be also taken into consideration. This contrasts with the results obtained by Tshen et al, with a one-year recurrence rate of 24% determined by pathological anatomy study<sup>11</sup>. Our observations have been clinical and we can only confirm that lesions do not recur insofar as visual and palpable appearance thereof.

Annemans et al.<sup>3</sup> also report an 83% efficacy in full clinical response in BCC cases, with a follow-up at 6 months, and an excellent cosmetic result in 93% of cases. Surrenti, using an experimental model very similar to ours, reports a full clinical regression in 89.4% cases of superficial BCC, and of 52.2% in those of nodular BCC. Cosmetic outcome was rated as excellent or good. Recurrence was observed in 2.4% successfully treated superficial BCC at 6 and 12 months after treatment discontinuation. On the other hand, Foley et al., using histological studies, reported the eradication of the tumour in 73% of cases<sup>5</sup>. A 10 year prospective study has recently been published which proves complete remission in 75% of lesions treated with a single session, which increases to 87% when two sessions are applied. All recurrences were observed before the third year post-treatment<sup>6</sup>. Our data indicates a very significant reduction in size in 100% of tumours treated, with complete remission in 91.6% of superficial BCC. However, in 66.6% of the nodular BCC cases, the



tumours did not completely disappear, in particular those of considerable size. Patients stated they were satisfied or very satisfied in 90% of cases. At the one-year follow-up none of the tumours which had experienced full clinical remission reappeared.

The efficacy of PDT in cases of AV has been recently reviewed, but the methodology and results are variable <sup>12</sup>). The first clinical trial using ALA in the treatment of AV was reported by Hongcharu et al. <sup>13</sup>). Significant clinical improvement was evident after 4 weekly ALA light treatments. Since then, many PDT procedures have been used, and almost all of the studies have obtained satisfactory results. One of the most recent studies uses Indole-3-acetic-acid (IAA) as a sensitizer, plus green light, once a week over 5 weeks. A significant reduction in the number of inflammatory and non-inflammatory lesions was observed, with a clear improvement as of the second week of treatment <sup>7</sup>). A very interesting controlled clinical trial by Horfelt et al. looked at 30 individuals with moderate-to-severe inflammatory acne vulgaris lesions <sup>14</sup>). Three sessions at two week intervals were carried out. Three months after the last treatment, a reduction of 54% was observed in the total number of lesions. Our study indicates a very specific therapeutic regimen which yields good or excellent results in 74% of cases, and patients reported being satisfied or very satisfied in 89%. The follow-up after one year showed variations (mostly improvements) which were attributed to good compliance with the treatment prescribed.

Kohl et al. have reviewed the literature published on the efficacy of photodynamic skin rejuvenation up to 2012 <sup>9</sup>). They conclude that PDT takes up a middle position between ablative and non-ablative skin rejuvenation

both with regard to effectiveness and side effects. Zane et al., using a similar procedure (MAL-PDT, LED red light, 37J/cm<sup>2</sup>), have observed a reduction in mottled hyperpigmentation, fine lines, roughness and sallowness, in 20 patients <sup>15</sup>). Issa et al., using the same method in 14 patients, have observed improvements in wrinkles, texture and firmness of photoaged skin <sup>16</sup>). Our study proves a significant reduction of 1.05 points on the Dover scale, which fundamentally measures the same parameters. 64% of the patients obtained good or excellent results and 96% stated they were satisfied or very satisfied with the result. At the one-year follow-up, the results were maintained or improved (not reaching statistical significance) probably due to the topical maintenance treatment. However, the hypothesis that photorejuvenating effects may be delayed as a result of long term histological changes has been considered <sup>9,16</sup>).

We stress that our study has used a radiation dose of 105J/cm<sup>2</sup>, higher than that usually described in the literature, as well as the fact that the patients in the study mostly sought a fast and effective treatment, and showed little willingness to undergo continued applications of topical treatments. We conclude that PDT has provided an effective solution for these four conditions, offering a significant improvement in the lesions which was objectively ascertained by the therapist, the patient and expert assessors. This improvement was obtained in the short term and enables better therapeutic adherence to topical maintenance treatments in the long term. The patient learns that the skin must be looked after by using sun cream and specific treatments for each individual and condition.

## References

- 1: Ruíz Ávila J, Rebollo Domínguez N. Terapia fotodinámica en dermatología. *Dermatología Rev Mex* 2009; 53: 178-186.
- 2: Tarstedt M, Rosdahl I, Berne B, Svanberg K, Wenberg AM. A randomized multicenter study to compare two treatment regimens of topical methyl aminolevulinate (Metvix®)-PDT in actinic keratosis of the face and scalp. *Acta Derm Venereol* 2005; 85: 424-428.
- 3: Annemans L, Caekelbergh K, Roelandts R, et al. Real-life practice study of the clinical outcome and cost-effectiveness of photodynamic therapy using methyl aminolevulinate (MAL-PDT) in the management of actinic keratosis and basal cell carcinoma. *Eur J Dermatol* 2008; 18: 539-546.
- 4: Surrenti T, De Angelis L, Di Cesare A, Fagnoli MC, Peris K. Efficacy of photodynamic therapy with methyl aminolevulinate in the treatment of superficial and nodular basal cell carcinoma: an open-label trial. *Eur J Dermatol* 2007; 17: 412-415.
- 5: Foley P, Freeman M, Menter A et al. Photodynamic therapy with methyl aminolevulinate for primary nodular basal cell carcinoma: results of two randomized studies. *Int J Dermatol* 2009; 48: 1236-1245.
- 6: Christensen E, Mork C, Skogvoll E. High and sustained efficacy after two sessions of topical 5-aminolaevulinic acid photodynamic therapy for basal cell carcinoma: a prospective, clinical and histological 10-year follow-up study. *Br J Dermatol*

- 2012; 166: 1342-1348.
- 7: Huh SY, Na JI, Huh CH, Park KC. The effect of photodynamic therapy using indole-3-acetic acid and green light on acne vulgaris. *Ann Dermatol* 2012; 24: 56-60.
- 8: Uebelhoer NS, Dover JS. Photodynamic therapy for cosmetic applications. *Dermatol Ther* 2005; 18: 242-252.
- 9: Kohl EA, Karrer S. Photodynamic skin rejuvenation. *Photon Lasers Med* 2012; 1: 27-33.
- 10: Dover JS, Bhatia AC, Stewart B, Arndt KA. Topical 5-aminolevulinic acid combined with intense pulsed light in the treatment of photoaging. *Arch Dermatol* 2005; 141: 1247-52.
- 11: Tshen EH, Wong DS, Pariser DM. Photodynamic therapy using aminolaevulinic acid for patients with nonhyperkeratotic actinic keratoses of the face and scalp: phase IV multicentric clinical trial with 12-month follow-up. *Br J Dermatol* 2006; 155: 1262-1269.
- 12: <http://www.skintherapyletter.com/2007/12.10/1.html>
- 13: Hongcharu W, Taylor CR, Chang Y, Aghassi D et al. Topical ALA-photodynamic therapy for the treatment of acne vulgaris. *J Invest Dermatol* 2000; 115: 183-192.
- 14: Horfelt C, Funk J, Frohm-Nilsson M et al. Topical methyl aminolaevulinate therapy for treatment of facial acne vulgaris: results of a randomized, controlled trial. *Br J Dermatol* 2006; 155: 608-613.
- 15: Zane C, Capezzeri R, Sala R, Venturini M, Calzavara-Pinton P. Clinical and echographic analysis of photodynamic therapy using methylaminolevulinic acid as sensitizer in the treatment of photodamaged facial skin. *Lasers Surg Med* 2007; 39: 203-209.
- 16: Issa MC, Piñeiro-Maceira J, Vieira MT, Olej B, Mandarim-de-Lacerda CA, Luiz RR, Manela-Azulay M. Photorejuvenation with topical methyl aminolevulinic acid and red light: a randomized, prospective, clinical, histopathologic and morphometric study. *Dermatol Surg* 2010; 36: 39-48.